



GUIDELINE

Achondroplasia

Scope (Staff):	Nursing and Medical Staff
Scope (Area):	NICU KEMH, NICU PCH, NETS WA and KEMH Postnatal Wards

Child Safe Organisation Statement of Commitment

CAHS commits to being a child safe organisation by applying the National Principles for Child Safe Organisations. This is a commitment to a strong culture supported by robust policies and procedures to reduce the likelihood of harm to children and young people.

This document should be read in conjunction with this [disclaimer](#)

Aim

To provide consistent management and follow up to infants and families of infants with Achondroplasia.

Risk

Infants with Achondroplasia may not receive the correct management and follow-up.

Background

- Achondroplasia is the most common cause of disproportionate short stature, with 3-5 children born with the condition each year in WA. It is characterised by rhizomelic short stature, macrocephaly, frontal bossing and midface retrusion. Life span is normal, although craniocervical junction compression increases the risk of death in infancy.
- It is inherited in an autosomal dominant manner with complete penetrance. Around 80% of individuals have achondroplasia as a result of a new mutation (de novo) and have parents with normal stature.
- It is not easily identified on routine ultrasound during pregnancy, therefore it is most commonly diagnosed either later in pregnancy when a scan is done for another reason, or at some point after the baby is born.
- The diagnosis of Achondroplasia can be established solely based on the characteristic clinical and radiological features. *FGFR3* gene testing is done in uncertain cases, for confirmation of the clinical diagnosis and in prenatal settings when achondroplasia is suspected.

Clinical Description

The figure below represents the common clinical features and medical complications in individuals with Achondroplasia.

ACHONDROPLASIA

Skeletal features

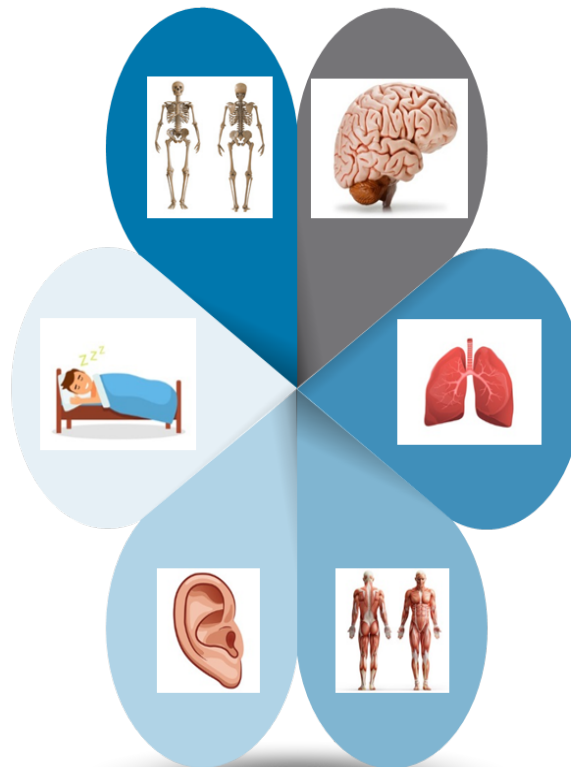
- Short stature with rhizomelic shortening of limbs
- Head/face: macrocephaly, frontal bossing, midface retrusion
- Elbow: limitation of extension & rotation
- Hands: brachydactyly
- Spine: pronounced lumbar lordosis, kyphosis
- Knees: genu varum
- Hypermobility of knees, hips & most other joints

Sleep features

- Risk of central apnoea secondary to narrow craniocervical junction

Other features

- Middle ear dysfunction
- Obesity



Neurological features

- Hydrocephalus (due to foramen magnum stenosis)
- Narrow craniocervical junction
- Spinal stenosis
- Intelligence in average range unless severe CNS complications

Respiratory issues

- Risk of central apnoea secondary to narrow craniocervical junction
- Restrictive respiratory disease

Muscle Tone

- Hypotonia in infancy
- Gross motor delays
- Snowplowing (using hands and feet to facilitate movement)

Radiological Features

1. Short and robust tubular bones.
2. Proximal femoral radiolucency.
3. Narrowing of the interpedicular distance of the lumbosacral spine (normally widens in a caudal direction).
4. Square ilia and horizontal acetabulae.
5. Narrow sacrosciatic notch.
6. Mild generalised metaphyseal changes.
7. Brachydactyly / trident configuration of fingers.

Antenatal Consultation

If the diagnosis of achondroplasia is suspected or known antenatally the mother should be offered an antenatal consultation with a Neonatal Consultant to develop a Neonatal Management Plan for the baby.

Neonatal Management

- Maintain appropriate handling of baby, by parents and staff to protect neck/airway:
- Cot card highlighting the need for careful handling.
- Positioning and handling of babies with Achondroplasia after birth
<https://www.schn.health.nsw.gov.au/fact-sheets/achondroplasia-positioning-and-handling-of-babies-with-achondroplasia> (to be printed and placed in plastic sleeve on cot).
- Measure and plot weight, length and head circumference on Achondroplasia-specific growth charts.
https://www.schn.health.nsw.gov.au/files/attachments/reh4033_growth_charts_fan_o_crops.pdf
- Clinical examination by Senior Neonatal Registrar or Consultant in the first 24 hours.
- Hypotonia, apnoea, feeding, colour change.
- Prior to discharge or within the first 6 weeks, request a MRI of cervical spine / craniocervical junction /brain and an Achondroplasia Foramen Magnum Score (AFMS) (feed and wrap technique)
- Request Genetic review as inpatient.
- Skeletal survey (if diagnosis suspected but not yet confirmed - discuss with Genetics if diagnosis is unclear).
- Request Physiotherapist review by e-referral (KEMH Physio tick URGENT/ Responder Natasha Amery). AND page #3121 weekdays or #3120 weekends

Parental Education Prior to Discharge

- Physiotherapist / ward staff on site – handling and positioning guidelines / demonstration.
- Car seat assessment by physiotherapist **before** discharge.
- CPR education / safe sleep guideline.
- Rural / regional families – advice re having an adult travelling in back seat with baby during trip home and suitable breaks if journey a significant distance.

Discharge Planning and Referrals

Provide parents with information about available resources

- <https://sspa.org.au/> (Parent representative for WA: Suzann Franklin landsfranklin@bigpond.com; 08 90413220)
- <https://medlineplus.gov/genetics/condition/achondroplasia/>

Referrals to be made by Neonatal Team

1. PCH Rehabilitation Medicine Early Intervention Service (Achondroplasia) (state “Diagnosis Achondroplasia” in referral).
2. Genetic Services via e-referral from public hospitals or through the Central Referral Service (state “Diagnosis Achondroplasia” in referral)
3. PCH Sleep Service (state “newborn with achondroplasia, for sleep study at 6 weeks of age”). If more urgent (Respiratory concerns, abnormal craniocervical junction MRI) – discuss with Respiratory consultant on call.
4. Hearing assessment - refer **all** infants with achondroplasia to PCH Audiology/ ENT.

References and related external legislation, policies, and guidelines


- <https://sspa.org.au/> (Parent representative for WA: Suzann Franklin landsfranklin@bigpond.com; 08 90413220)
 - <https://medlineplus.gov/genetics/condition/achondroplasia/>
 - <https://www.schn.health.nsw.gov.au/fact-sheets/achondroplasia-positioning-and-handling-of-babies-with-achondroplasia>
 - https://www.schn.health.nsw.gov.au/files/attachments/reh4033_growth_charts_fano_crops.pdf
1. Etus, V. and S. Ceylan, The role of endoscopic third ventriculostomy in the treatment of triventricular hydrocephalus seen in children with achondroplasia. *J Neurosurg*, 2005. 103(3 Suppl): p. 260-5.
 2. Swift, D., L. Nagy, and B. Robertson, Endoscopic third ventriculostomy in hydrocephalus associated with achondroplasia. *J Neurosurg Pediatr*, 2012. 9(1): p. 73-81.
 3. Hecht, J.T., et al., Obesity in achondroplasia. *Am J Med Genet*, 1988. 31(3): p. 597-602.
 4. Wynn, J., et al., Mortality in achondroplasia study: a 42-year follow-up. *Am J Med Genet A*, 2007. 143a(21): p. 2502-11.
 5. Wigg, K., et al., The neuropsychological function of children with achondroplasia. *Am J Med Genet A*, 2016. 170(11): p. 2882-2888.
 6. Hecht, J.T., et al., Mortality in achondroplasia. *Am J Hum Genet*, 1987. 41(3): p. 454-64.
 7. Pauli, R.M., et al., Prospective assessment of risks for cervicomedullary-junction compression in infants with achondroplasia. *Am J Hum Genet*, 1995. 56(3): p. 732-44.
 8. Fowler, E.S., et al., Biophysical bases for delayed and aberrant motor development in young children with achondroplasia. *J Dev Behav Pediatr*, 1997. 18(3): p. 143-50.
 9. Ireland, P.J., et al., Developmental milestones in infants and young Australasian children with achondroplasia. *J Dev Behav Pediatr*, 2010. 31(1): p. 41-7.
 10. Ireland, P.J., et al., Development in children with achondroplasia: a prospective clinical cohort study. *Dev Med Child Neurol*, 2012. 54(6): p. 532-7.
 11. Waller, D.K., et al., The population-based prevalence of achondroplasia and thanatophoric dysplasia in selected regions of the US. *Am J Med Genet A*, 2008. 146a(18): p. 2385-9.

12. Trotter, T.L. and J.G. Hall, Health supervision for children with achondroplasia. *Pediatrics*, 2005. 116(3): p. 771
13. Bagley, C.A., et al., Cervicomedullary decompression for foramen magnum stenosis in achondroplasia. *J Neurosurg*, 2006. 104(3 Suppl): p. 166-72.
14. Waters, K.A., et al., Treatment of obstructive sleep apnea in achondroplasia: Evaluation of sleep, breathing, and somatosensory-evoked potentials. *American Journal of Medical Genetics*, 1995. 59(4): p. 460-466.
15. Horton, W.A., et al., Standard growth curves for achondroplasia. *J Pediatr*, 1978. 93(3): p. 435-8.
16. Mogayzel, P.J., Jr., et al., Sleep-disordered breathing in children with achondroplasia. *J Pediatr*, 1998. 132(4): p. 667-71.
17. Langer, L.O., Jr., P.A. Baumann, and R.J. Gorlin, Achondroplasia. *Am J Roentgenol Radium Ther Nucl Med*, 1967. 100(1): p. 12-26.
18. Wright, M.J. and M.D. Irving, Clinical management of achondroplasia. *Archives of Disease in Childhood*, 2012. 97(2): p. 129.
19. Hoover-Fong, J. et al., Health Supervision for people with Achondroplasia. *Am Acad Ped*, 2020. 145(6): p. 1-19.

Useful resources (including related forms)

Neonatal Management Plan MR409.90

This document can be made available in alternative formats on request.

Document Owner:	Neonatology		
Reviewer / Team:	Neonatology / Genetics / Respiratory Medicine / PCH Rehabilitation		
Date First Issued:	February 2021	Last Reviewed:	October 2024
Amendment Dates:		Next Review Date:	October 2027
Approved by:	Neonatology Coordinating Group	Date:	17 th October 2024
Endorsed by:	Neonatology Coordinating Group		
Standards Applicable:	NSQHS Standards:  Child Safe Standards: 1,10		

Printed or personally saved electronic copies of this document are considered uncontrolled



Healthy kids, healthy communities

Compassion

Excellence

Collaboration

Accountability

Equity

Respect

Neonatology | Community Health | Mental Health | Perth Children's Hospital